



# Arthroscopic reconstruction of the anterior cruciate ligament with patellar-tendon autograft and interference screw fixation

## THE RESULTS AT SEVEN YEARS

N. M. Jomha, L. A. Pinczewski, A. Clingeleffer, D. D. Otto

*From the Australian Institute of Musculo-Skeletal Research, Sydney, Australia*

**D**eficiency of the anterior cruciate ligament (ACL) is a common disorder which can lead to changes in lifestyle. We followed 59 patients who had had arthroscopic reconstruction of the ACL using a central-third patellar-tendon autograft for seven years to assess the long-term effectiveness of recent advances in reconstruction of the ACL. The standard criteria for evaluation of the International Knee Documentation Committee, the Lysholm knee score and measurements using the KT 1000 arthrometer all showed satisfactory results. Deterioration in the clinical performance after seven years was associated with osteoarthritic changes and correlated with chronic ligament injuries and meniscectomy. There were three traumatic and three spontaneous ruptures.

We believe that the procedure can be successful, but remain concerned about failure of the graft and osteoarthritis. The results raise questions about the best time to operate and suggest that early surgery may reduce the risk of osteoarthritis.

*J Bone Joint Surg [Br] 1999;81-B:775-9.*

*Received 15 December 1997; Accepted after revision 23 June 1998*

Rupture of the anterior cruciate ligament (ACL) is a common sports injury which often markedly reduces athletic activity and the quality of life. The ACL is the primary stabiliser against anterior translation of the tibia on the femur<sup>1</sup> and is important in counteracting rotation and valgus stress.

In activities which demand pivoting, cutting and side-stepping, such as rugby, football, netball and field hockey, deficient function of the ACL leads to instability. This results in recurrent injuries and an increased risk of intra-

articular damage, including meniscal tears. Reconstruction of the ACL often allows patients to resume these activities and can also delay the onset of osteoarthritis associated with the loss of meniscal function.<sup>2-6</sup>

In recent years there have been rapid advances in techniques for ligament reconstruction and rehabilitation. These include open surgical repair of the ruptured ligament, open reconstruction using an intra-articular graft and extra-articular augmentation, arthroscopic reconstruction with extra-articular augmentation, and arthroscopic intra-articular reconstruction.<sup>7-11</sup> The method using a patellar-tendon autograft is popular.<sup>12-14</sup> Recent research has shown that this procedure is effective in the short term,<sup>8,9,13,15-17</sup> but there is little information regarding the long-term outcome of this or other procedures for reconstruction of the ACL.

We describe the results in patients who had reconstruction of the ACL with a central-third patellar-tendon autograft at seven years.

### Patients and Methods

The senior author (LAP) carried out arthroscopic reconstruction using a central-third patellar-tendon autograft on 80 patients between March and November 1989. Patients with multiple ligamentous injuries were excluded except for those with associated injuries of the medial collateral ligament (MCL). All deficiencies of the ACL were demonstrable by a positive Lachman test and/or a pivot shift test.

Patients with ACL deficiency, who had neither repeated episodes of instability nor the intention of participating in high-risk activities, were advised against surgery. Reconstruction was recommended for those intending to resume activities involving pivoting, cutting and side-stepping. Of these, 21 were operated on in the acute phase (less than three weeks after injury) and 11 in the subacute phase (from 3 to 12 weeks after injury). Chronic ACL ruptures of more than 12 weeks old were present in 27 patients, all of whom had failed to benefit from a sport-specific rehabilitation programme and were experiencing recurrent episodes of instability. There were associated MCL injuries in 16 patients. Reconstruction of both the MCL and ACL was carried out in 11 patients, while five were treated by bracing. The findings at operation were

N. M. Jomha, FRCS C, Orthopaedic Surgeon  
L. A. Pinczewski, FRACS, Consultant Orthopaedic Surgeon  
A. Clingeleffer, BAppSci, Research Assistant  
D. D. Otto, FRCS C, Orthopaedic Surgeon  
Australian Institute of Musculo-Skeletal Research, 286 Pacific Highway,  
New South Wales 2065, Crows Nest, Australia.

Correspondence should be sent to Dr L. A. Pinczewski.

©1999 British Editorial Society of Bone and Joint Surgery  
0301-620X/99/58644 \$2.00

**Table I.** Meniscal status of the 59 patients at the time of ACL reconstruction

Meniscal status	Medial	Lateral
Intact	32	27
Damaged	6	6
Posterior horn	0	6
Sutured	3	5
Excised	18	15

reviewed retrospectively to establish associated meniscal injury (Table I).

The same technique was used in all operations. A central-third patellar-tendon autograft with bone blocks was taken from the ipsilateral knee and inserted through holes drilled in the tibia and femur. AO 6.5 mm fully threaded cancellous screws achieved interference fixation. Where there was abnormal MCL laxity, the proximal origin of the ligament was advanced just before fixation of the ACL graft to the tibia, and fixed with a staple. The mean tourniquet time was 76 minutes (43 to 135) and the mean theatre time 91 minutes (62 to 150).

For 24 hours after the operation, flucloxacillin and gentamicin were administered intravenously and the knees were subjected to continuous passive motion from 30° to 90° for 48 hours. Patients were non-weight-bearing in a rehabilitation brace (30° to 90°) for four weeks. Inspection of the wound was carried out and the sutures removed ten to 14 days after surgery. Aggressive physiotherapy was started at 48 hours to achieve a full range of movement (ROM) and adequate muscle strength. Follow-up visits were at six weeks and at three, six and 12 months. No return to high-risk activities was allowed until nine months after operation.

Five years after surgery, 68 patients were reviewed, 12 having been lost to follow-up. Over the next two years contact with six more patients was lost. Three patients suffered traumatic ruptures of the graft at 29, 44 and 56 months. This left 43 men and 16 women with a mean age of 26 years (SD 7; 16 to 46) available for examination at seven years. Reconstruction of the ACL had been carried out on the left knee in 32 patients and on the right knee in 27. All these assessments were by independent examiners.

The Lysholm knee score was used to document subjective symptoms at each follow-up. Ligament stability, ROM, atrophy of the thigh and knee tenderness were assessed at the one-year follow-up.

The grading system recommended by the International Knee Documentation Committee (IKDC),<sup>18</sup> which incorporates multiple subjective and objective criteria, was used at the five-year and seven-year follow-up. The system became available only in 1993 and therefore called for retrospective grading of the status of the knee before injury. The remaining data were collected prospectively. Subjective assessment of function, symptoms and level of activity was made according to IKDC recommendations. Objective assessment of ROM, ligamentous laxity (Lach-

man, anterior drawer and pivot shift tests), compartmental findings, tenderness at the harvest site and functional testing were made according to IKDC guidelines. Pain was assessed with patients kneeling at 90° on a standardised carpet surface. The site of pain was recorded and rated on a scale of one to ten, with 1 indicating no pain and 10 indicating severe pain. We noted the thigh measurements at five and seven years and carried out tests with a KT 1000 arthrometer (89N force) on 45 patients. Of the remainder, nine had contralateral ACL injuries and five were unavailable. Radiological examination was carried out with AP, lateral, skyline and 30° posteroanterior weight-bearing views.

We used the SPSS 6.0 for Windows program for statistical analysis. The chi-squared test and three-way frequency analysis were used to assess the relationship between the state of the joint at operation and the outcome variables at seven years. We used Cochran's Q-test and McNemar's test to assess changes in outcome variables over time, and the chi-squared test to assess associations between the outcome variables at seven years. A level of significance of  $p < 0.05$  was used.

## Results

Of the 59 patients seen at follow-up at seven years, logistic regression analysis showed no significant associations between the clinical results and age, gender, the level of activity before injury and concurrent operation on the MCL.

**Subjective assessment.** At seven years, 56 patients rated their knees as normal or nearly normal. Three regarded their function as abnormal, compared with two at the five-year follow-up. Of the three patients who complained of abnormal function of the knee, one had severe osteoarthritic change, another experienced pain on light activity, and the third considered function to be only moderately affected. Three patients regarded their level of activity as abnormal and one as severely abnormal. In two of these, failure of the graft had occurred. The other 55 patients rated their level of activity as normal or nearly normal.

**Symptoms.** At seven years, all except nine patients could undertake moderate to strenuous activities without pain; eight complained of pain on light activity, one when sedentary. These results were similar to those at one year but worse than at five years when only one patient complained of pain on light activity.

Moderate to strenuous activity caused minimal swelling in 54 patients at the seven-year review. Swelling accompanied light activity in four patients, and one patient experienced swelling when sedentary. These results were similar to those at one year. At the five-year review no patient had swelling on light or sedentary activity.

At seven years two patients complained that their knees gave way fully, one on light activity and the other on moderate activity. These results were similar to those at the

**Table II.** Clinical stability of 59 patients at seven years

Grade*	Lachman	Pivot shift	Anterior drawer
0	35	45	56
1	21	13	3
2	3	1	0

\* grade 0, no difference from the contralateral knee; grade 1, slight difference; grade 2, marked difference

five-year review, and an improvement on those after one year, when 12 patients complained that their knees gave way fully. At both five and seven years three patients reported partial instability on moderate to strenuous activity.

**Range of movement.** At seven years, 12 patients had lost extension of 3° to 5°, compared with three at five years. In 44 patients (55 at five years) loss of extension was less than this. Loss of flexion was less than 5° in 55 patients at seven years, compared with 57 at five years and 43 at one year. Only one patient had loss of flexion of 15° to 25° at the seven-year follow-up.

**Ligament stability.** Table II shows the results of the Lachman, anterior drawer and pivot shift tests at the seven-year follow-up. Although two patients had increased laxity, there was no statistical significance. When we carried out KT 1000 testing on 45 patients at the seven-year review, the mean side-to-side difference in AP translation was 1.7 mm (SD 1.8; median 2.0 mm). The side-to-side difference was less than 3 mm in 29 of the 45 patients, and 3 mm to 5 mm in 15 patients. Only one patient had more than 5 mm of side-to-side difference.

**Overall IKDC grade.** The worst score in any of the categories (subjective assessment, symptoms, ROM and ligament stability) was used as the patient's IKDC grade. Figure 1 shows IKDC grades at five and seven years.

**The harvest site.** Moderate numbness, tenderness or irritation occurred in six patients, and slight symptoms in 20. The remaining 33 patients had no discomfort at the harvest site. When questioned specifically about pain on kneeling, four patients had pain over the patella, five over the patellar tendon, and three over the tibial tubercle. The other 47 had no pain on kneeling. The pain was given a mean score of three out of ten (two to six). These results were similar to those at the five-year evaluation in which 48 of 59 patients had no pain, and those who did have pain rated it on average at two out of ten.

**Radiological findings.** There was a trend towards radiological deterioration in 53 patients who had radiographs taken at both five and seven years (Table III). By this time

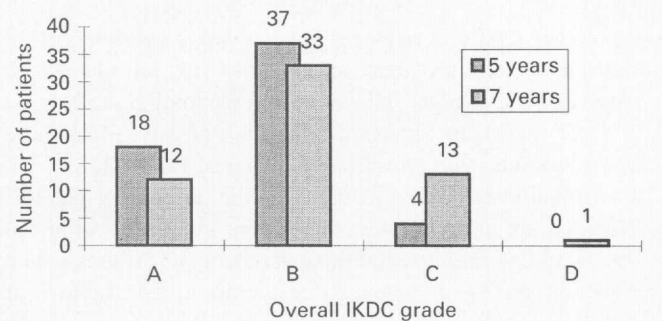


Fig. 1

The IKDC grades for the 59 patients five and seven years after surgery.

not all preoperative films were still available for comparison. There was a significant relationship between the radiological findings and the timing of surgery. Osteoarthritic changes were more advanced when reconstruction of the ACL ligament had been carried out on injuries over 12 weeks old ( $p < 0.05$ ).

**Lysholm knee score.** Lysholm knee scores of more than 83 (good or excellent) were achieved in 48 of 59 patients at seven years. The median scores were 94 (54 to 100) at seven years, 94 (55 to 100) at five years, and 90 (69 to 100) at one year.

**Thigh atrophy.** At seven years, 39 patients had no sign of muscle wasting. In five patients, there was a difference of 0.5 cm in thigh circumference, and in 11 there was a difference of 1 cm. The remaining four patients had differences of 1.5 to 2 cm. This was similar to the findings at five years, and much better than at one year, when only 26 of the 59 patients had no evidence of wasting.

**Meniscal associations.** Of the 55 patients examined radiologically at seven years, only 17 had normal medial and lateral menisci. A portion of the lateral meniscus had been lost or damaged in 14 patients, of the medial meniscus in nine and 15 had damaged or lost a portion of both menisci. Meniscectomy was required at the time of reconstruction in 67% of chronic injuries, compared with 31% in acute or subacute injuries. This difference was significant ( $p < 0.025$ ). Furthermore, there was increased osteoarthritic change when meniscal damage had been noted or meniscectomy carried out ( $p < 0.02$ ).

Degenerative change as demonstrated by radiography was most severe in patients who had lost or damaged both menisci. Medial meniscectomy was more directly correlated ( $p < 0.001$ ) with degenerative change than lateral meniscectomy ( $p < 0.05$ ). Other variables, such as minor lateral

**Table III.** Radiological assessment of 53 patients at five and seven years

IKDC grade	Description	Follow-up (yr)	
		5	7
A	Normal	27	23
B	Subchondral sclerosis, osteophytes, flattening of femoral condyle	22	22
C	Increased sclerosis, larger osteophytes, narrowing of the joint space	4	7
D	Above changes and <2 mm of joint space	0	1

or medial meniscal damage, tears of the posterior horn or damage to the articular surface, did not correlate with osteoarthritic change. At operation the chondral surfaces of 27% of the knees appeared abnormal. Nearly all of these were in joints with chronic deficiency of the ACL.

**Complications.** Complications in the initial 68 patients included six graft failures; there were three after injury at 29, 44 and 56 months, and three spontaneous failures which were noted at seven years. After operation, five ruptures of the ACL occurred in the opposite knee. It was necessary to remove the screws in seven cases. Manipulation under anaesthesia was required in three patients at 3, 4 and 7 months, respectively, and arthroscopic division of adhesions was needed in two at 6 and at 9 months. One postoperative infection was treated by lavage and removal of the screw. Three medial meniscectomies and four arthroscopic debridements became necessary later.

## Discussion

IKDC grades incorporate multiple subjective and objective criteria. According to the IKDC criteria knees were graded normal (A), nearly normal (B), moderately abnormal (C) and severely abnormal (D). Irrgang et al<sup>19</sup> found that they could distinguish differences in outcome between knees rated D and those rated A, B or C, or between knees rated C and those rated A or B, but not between those rated A or B. Accordingly, it may be better to consider knees of grades A and B as one group and those of grades C and D as another. This helps to delineate the abnormal results found in grades C or D.

At the seven-year follow-up, most patients had function of grade A or B. Low IKDC grades were associated with meniscectomy, radiologically-demonstrable changes and ligamentous laxity. There was no relationship between IKDC grade and the postoperative levels of activity. This suggests that even people with stable and symptom-free knees do not necessarily resume preoperative activities, and that changes in individual preferences may account for some modification in level of activity.

Diminution of pain improved one patient's grade from C/D to A/B between the five- and seven-year evaluations. Overall, the IKDC results deteriorated between five and seven years with only 35 patients maintaining the five-year grade. In the 11 patients whose results deteriorated from grades A/B to C/D, six complained of increased pain, two of extension loss, and one of increased partial instability. The other two had graft failures and experienced deterioration in all areas. Ten of these 11 had radiological evidence of osteoarthritic change. This suggests that the development of such change may have led to the decline in IKDC grade. Although failure of the graft occurred in three patients, it was not the most common cause of deterioration of grade.

Lysholm scores and functional ratings at seven years showed moderate subjective satisfaction. Pain and swelling

tended to increase in severity and frequency and were a major reason for the decline in IKDC grades between five and seven years. Full or partial instability was found relatively seldom. It is important to note that three patients who had traumatic ruptures before the five-year follow-up were not included in this review.

Long-term tenderness and pain on kneeling occur in some 20% (19% in our study) of patients who undergo patellar-tendon autografts.<sup>13,20-22</sup> After seven years, tenderness at the donor site was present in 44% of our patients. Although this did not detract from the functional results, it did affect patient satisfaction and IKDC grade.

Of patients who lost extension between the five and seven years, 75% had radiologically-demonstrable osteoarthritic changes, which suggests that degeneration of the articular surfaces of the knee was responsible for the decrease in ROM.

There was no significant difference in knee stability between the first and last follow-up. Two patients developed increased abnormal laxity between five and seven years. Neither had been injured. Another, also with no history of trauma, had abnormal laxity both five and seven years after reconstruction of the ACL. KT 1000 testing (89 N force) at the seven-year follow-up showed an abnormal side-to-side difference of more than 5 mm in only one patient.

We do not know why three grafts failed spontaneously; all three were stable at one year, and two after five years. During revision operations we have observed that the patellar-tendon graft retains its ribbon-like insertion at the site of femoral attachment, and can be perforated by bone growing through the tendon. This raises concerns about the long-term integrity of patellar-tendon autograft.

The association between meniscectomy and osteoarthritis has been well documented.<sup>2-6</sup> In our study, meniscectomy was more often necessary in chronic than in acute or subacute ACL injuries. There was a definite association with radiological changes. Medial meniscectomy was more often associated with severe radiologically-demonstrable degenerative change than lateral meniscectomy, but both relationships were significant. Meniscal damage alone, meniscal suture, or damage to the articular surface did not seem to correlate with radiological evidence of deterioration, but the samples were too small to be reliable.

Meniscectomy was associated with low IKDC grades. Patients undergoing meniscectomy had a 34% chance of an abnormal or severely abnormal result at seven years compared with 14% of patients with intact menisci. Increased pain, swelling and loss of extension were the common reasons for progression of IKDC grades into the abnormal range. These symptoms may have been due to progressive osteoarthritic changes associated with the increased rate of meniscectomy. The results suggest that reconstruction of the ACL in the acute or subacute injury phase may decrease the risk of osteoarthritic degeneration.

The long-term results were moderately successful. There

was no evidence of stretching of the graft in most patients, but there were three traumatic and three spontaneous failures. After five years, pain and swelling increased and the IKDC grades deteriorated. This was consistent with the increased degenerative changes noted on radiographs at seven years.

The results of our study suggest that reconstruction of the ACL should be done early in the 'at-risk' patient, before further damage to the joint occurs. We believe that arthroscopic reconstruction of the ACL using the central-third patellar-tendon can be successful in the long term, but some failures certainly occur. Unresolved concerns about traumatic and spontaneous failure of the graft, the presence and progression of osteoarthritis and the timing of surgery require further investigation.

No benefits in any form have been received or will be received from a commercial party related directly or indirectly to the subject of this article.

## References

1. Levy IM, Torzilli PA, Warren RF. The effect of medial meniscectomy on anterior-posterior motion of the knee. *J Bone Joint Surg [Am]* 1982;64-A:883-8.
2. Lynch M, Henning CE. Osteoarthritis in the ACL deficient knee. In: Feagin JA, ed. *The crucial ligaments: diagnosis and treatment of ligamentous injuries about the knee*. New York: Churchill Livingstone, 1988: 385-91.
3. Ferretti A, Conteduca F, DeCarli A, Fontana M, Mariani PP. Osteoarthritis of the knee after ACL reconstruction. *Int Orthop* 1991; 15:367-71.
4. Jørgensen U, Sonne-Holm U, Lauridsen F, Rosenklint A. Long-term follow-up of meniscectomy in athletes. *J Bone Joint Surg [Br]* 1987;69-B:80-3.
5. Ranger C, Klestil T, Gloetzer W, Kemmler G, Benedetto KP. Osteoarthritis after arthroscopic partial meniscectomy. *Am J Sports Med* 1995;23:240-4.
6. Satku K, Kumar JP, Ngoi SS. Anterior cruciate ligament injuries: to counsel or operate? *J Bone Joint Surg [Br]* 1986;68-B:458-61.
7. Jackson DW, Jennings LD. Arthroscopically assisted reconstruction of the anterior cruciate ligament using a patella tendon bone autograft. *Clin Sports Med* 1988;7:785-700.
8. Marder RA, Raskind JR, Carroll M. Prospective evaluation of arthroscopically assisted anterior cruciate ligament reconstruction: patellar tendon versus semitendinosus and gracilis tendons. *Am J Sports Med* 1991;19:478-84.
9. Moyer RA, Betz RR, Iaquinio J, et al. Arthroscopic anterior cruciate reconstruction using the semitendinosus and gracilis tendons: preliminary report. *Contemp Orthop* 1986;12:17-23.
10. Friedman MJ. Arthroscopic semitendinosus (gracilis) reconstruction for anterior cruciate ligament deficiency. *Tech Orthop* 1988;2:74-80.
11. Bach BR. Arthroscopy-assisted patellar tendon substitution for anterior cruciate ligament insufficiency: surgical technique. *Am J Knee Surg* 1989;2:3-20.
12. Johnson RJ, Beynonn BD, Nichols CE, Renstrom PA. Current concepts review: the treatment of injuries of the anterior cruciate ligament. *J Bone Joint Surg [Am]* 1992;74-A:140-51.
13. Otero AL, Hutcheson L. A comparison of the doubled semitendinosus/gracilis and central third of the patellar tendon autografts in arthroscopic anterior cruciate ligament reconstruction. *J Arthroscopy* 1993;9:143-8.
14. Wojtys EM. *The ACL deficient knee*. Rosemont, USA: American Academy of Orthopaedic Surgeons Monograph Series, 1994:72-8.
15. Holmes PF, James SL, Larson RL, Singer KM, Jones DC. Retrospective direct comparison of three intraarticular anterior cruciate ligament reconstruction. *Am J Sports Med* 1991;19:596-9.
16. Buss DD, Warren RF, Wickiewicz TL, Galinat BJ, Panariello R. Arthroscopically assisted reconstruction of the anterior cruciate ligament with use of autogenous patellar-ligament grafts: results after twenty-four to forty-two months. *J Bone Joint Surg [Am]* 1993;75-A: 1346-55.
17. Sgaglione NA, Schwartz RE. Arthroscopically assisted reconstruction of the anterior cruciate ligament: initial clinical experience and minimal 2-year follow-up comparing endoscopic transtibial and two-incision techniques. *Arthroscopy* 1997;13:156-65.
18. Anderson AF. Rating scales. In: Fu FH, Harner CD, Vince KG, eds. *Knee surgery. Vol 1*. Baltimore: Williams and Wilkins, 1994:275-96.
19. Irrgang JJ, Ho H, Harner CD, Fu FH. Use of the international knee documentation committee guidelines to assess outcome following anterior cruciate ligament reconstruction. *AOSSM Specialty Day Atlanta*, 1996:30-1.
20. Sachs RA, Daniel DM, Stone ML, Garfein RF. Patellofemoral problems after anterior cruciate ligament reconstruction. *Am J Sports Med* 1989;17:760-5.
21. Johnson RJ, Eriksson E, Haggmark T, Pope MH. Five to ten year follow-up evaluation after reconstruction of the anterior cruciate ligament. *Clin Orthop* 1984;183:122-40.
22. Aglietti P, Buzzi R, D'Andria S. Patellofemoral problems after intraarticular anterior cruciate ligament reconstruction. *Clin Orthop* 1993;288:195-204.